

Sentinel Lymph Node Biopsy for Breast Cancer and Melanoma

by Joseph J. Bennett, MD

Breast cancer remains the most common malignancy diagnosed among women today. In 2005, breast cancer was projected to account for 213,000 new cancer diagnoses in women and 41,000 deaths.¹ Melanoma will account for 66,000 new cancer diagnoses and almost 8,000 deaths.¹ Unfortunately, these staggering numbers are on the rise.

Breast cancer and melanoma are similar in that both are surgically treated for cure by wide resection of skin and soft tissue. The most striking similarity between these two cancers, however, is their propensity to metastasize to regional lymph nodes. It is extremely rare for these cancers to spread systemically without first passing through the first draining lymph node basin. For this reason, the presence or absence of regional lymph nodes is the most significant prognostic variable that predicts survival for patients with either breast cancer or melanoma. Thus, the status of regional lymph nodes dictates staging, prognosis, treatment, and enrollment into clinical trials.^{2,3}

Just over a decade ago, regional nodal basins were assessed by complete lymph node dissections, either in the axilla, the groin, or in the neck, depending on the location of the primary tumor.⁴ The problem with this approach was that many patients did not ultimately have lymph node metastases and did not, therefore, benefit from more accurate staging or better locoregional control, although all patients suffered the morbidity of extensive surgery.⁵⁻⁶ In 1992, a new technique involving intraoperative lymphatic mapping was reported for the first time.⁷ This technique revolutionized the assessment of regional lymph nodes and is now known as sentinel lymph node (SLN) mapping, performed in combination with a sentinel lymph node biopsy (SLNB).⁷

SLNB Principles and Techniques

Morton and colleagues were the first to demonstrate that lymphatic drainage from a melanoma can be “mapped” by injecting the skin around the tumor with blue dye.⁷ Injected blue dye was shown to travel through lymphatic channels to the first, or “sentinel” lymph node that drains the tumor (Figure 1). After intense histologic analysis of the SLN, these investigators were able to show that the pathologic status of the SLN accurately reflected the pathologic status of the entire regional nodal basin. A positive SLN is associated with a higher chance of the remaining nodes containing metastases, while patients with negative SLNs infrequently have other nodes that contain tumor cells.^{7,8} SLN map-

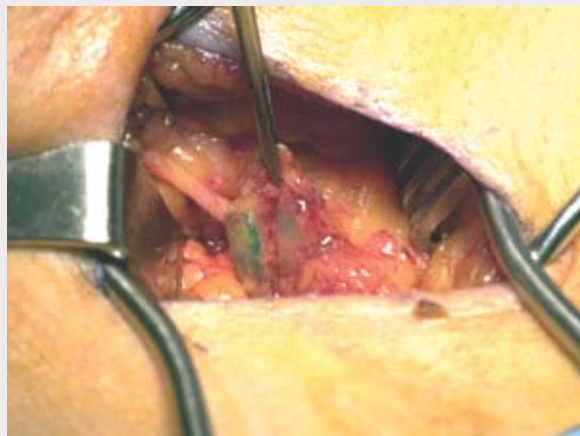
ping therefore spares approximately 80 to 85 percent of patients with melanoma and 65 to 70 percent of patients with breast cancer from having a complete lymph node dissection for what will ultimately be a negative nodal basin.⁷⁻¹⁰

The technique of SLN mapping has been significantly refined over the past decade. The accuracy of detecting the SLN when using blue dye alone is approximately 80 percent.⁷⁻¹⁰ In order to further increase the accuracy of detecting the SLN, a radiolabeled tracer such as technetium-99m-labeled sulfur colloid is also injected at the site of the primary tumor.¹¹ A lymphoscintigram is an X-ray obtained before surgery that localizes the radiolabeled SLN and visually directs the surgeon to the proper node(s) and basin for biopsy. The SLN is now considered “hot” with radioactivity and can be measured quantitatively by a gamma counter probe. The incision is targeted directly over the SLN by using the gamma probe to detect the area of highest radioactivity. The surgeon then follows the blue-colored lymphatic channels to the SLN, in addition to using the gamma counter to find the SLN with the most radioactivity (Figure 2). After excision, the blue and hot node is counted with the gamma probe *ex vivo* and the number is recorded. In addition to removing any blue nodes, any remaining nodes in the regional basin that are greater than 10 percent of the “hottest” node are also removed. Using these combined modalities, the accuracy of detecting the SLN has increased to between 92 and 98 percent.⁷⁻¹²

Pathologic Assessment of the Sentinel Node

Another significant stride in SLN mapping involves targeted histologic analysis by the pathologist. The patholo-

Figure 1. Isosulfan blue dye (1 percent) was injected into the skin immediately surrounding a melanoma. The blue dye travels into the lymphatic channels and is followed to the sentinel lymph node.



gist receives a single lymph node, or just a few nodes, which can be subjected to a much more intense and targeted analysis. In addition to performing many levels of tissue slicing with H&E (Hematoxylin and Eosin) staining, immunohistochemistry (IHC) is performed as a complement to H&E. IHC involves the use of tumor-specific antibodies to detect micrometastases. IHC confirms the presence of tumor cells in cases where H&E is not definitive, and has also been shown to detect an additional 8 to 12 percent of tumor cells that were missed by H&E staining.¹³⁻¹⁴ The clinical significance of micrometastases detected by IHC only is not completely clear at the present time.

Indications for SLN Biopsy in Melanoma and Breast Cancer

Patients with melanoma most likely to benefit from SLNB have an intermediate thickness (1.0-4.0 mm) lesion.⁷ The incidence of nodal metastases ranges from 6 percent for patients with a 1.0 mm melanoma to 35 percent in patients with a 4.0 mm melanoma.¹² For patients with melanoma <1.0 mm, other indications for SLNB include Clark IV depth, presence of tumor regression, and presence of ulceration.¹⁵ Some relative indications may include younger age, high number of mitoses, male gender, and axial location.¹⁶ Patients with thick melanoma (>4.0 mm) have a high incidence of systemic disease and should undergo a proper extent of disease evaluation. For patients without distant metastases or clinically positive nodes, SLNB should still be offered as it provides valuable staging and prognostic information.¹⁷

For patients with breast cancer, SLN mapping and biopsy is indicated for T1 and T2 lesions (<5cm), pro-

vided that there are no clinically palpable nodes.³ The incidence of finding a positive SLN is 30 to 35 percent for patients with early stage breast cancer.^{3,9-11} The incidence of finding a positive SLN in patients with ductal carcinoma *in situ* (DCIS) is so small that SLN mapping is not recommended for patients undergoing lumpectomy.³ However, SLN biopsy is acceptable for patients with DCIS when total mastectomy is to be performed, mainly because SLNB is impossible after all breast tissue is removed, and if invasive cancer is found in the specimen, the patient would be committed to axillary lymph node dissection (ALND).

Clinical Trials Involving SLN Mapping for Melanoma

Four major prospective randomized clinical trials are evaluating lymphatic mapping and SLNB for melanoma. The first two are the Multicenter Selective Lymphadenectomy Trial-I (MSLT-I) and the MSLT-II. The MSLT-I randomized patients with intermediate thickness melanoma to receive wide-excision and observation or wide-excision plus SLNB. If the SLNB revealed a positive node, patients then had a completion lymph node dissection (CLND). The goal of this study was to determine if early detection and management of regional nodes would improve survival. Patients who had wide-excision alone had a therapeutic lymph node dissection (TLND) only if clinical nodal recurrence was detected during the observation period. Results from the MSLT-I were recently presented at the 2005 ASCO meeting and demonstrated no difference in five-year overall survival between the two groups.¹⁸ However, 18 percent of patients treated by wide-excision alone had regional nodal recurrence, indicating that SLNB followed by CLND provides excellent locoregional nodal control. The goal of the MSLT-II is to determine if SLNB alone is adequate therapy for patients with a positive SLN, or if patients should proceed to CLND. The MSLT-II enrolls patients with intermediate thickness melanoma to wide excision with a SLNB and then randomizes patients with a positive SLN to either observation or CLND. Results from the MSLT-II are not yet available.

The hypothesis of the Florida Melanoma Trial (FMT) is that patients with a positive SLN who undergo CLND have no disease-free survival or overall survival advantage when

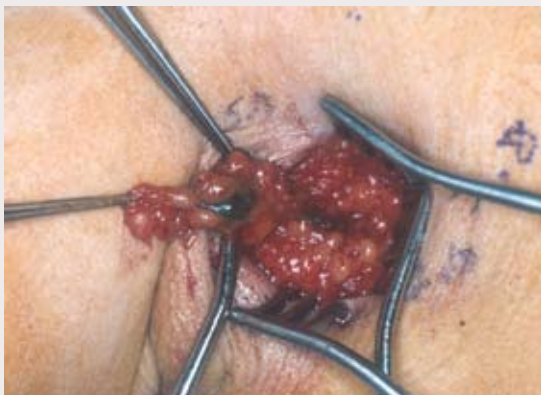

Figure 2. A small incision is targeted directly over the sentinel lymph node by measuring the radioactivity of the hot node with a gamma counter. The blue sentinel lymph node can be clearly distinguished and dissected free from surrounding tissue and (non-sentinel) lymph nodes.

compared to patients who have a SLNB alone, provided that all patients are also treated post-operatively with adjuvant IFN- α 2b (Interferon alpha 2-b). This trial further stratifies patients based on the method of detection of metastases in the SLN, as determined by H&E, IHC, and by quantitative PCR (polymerase chain reaction).

The Sunbelt Melanoma Trial (SBMT) has a very complex study design with a total of seven arms in the randomization process. All patients with melanoma >1.0 mm had SLN mapping and biopsy, with histologic analysis for micrometastases determined by H&E and IHC. All patients with a histologically positive SLN had CLND, and then patients were further randomized to either observation or adjuvant IFN- α 2b. This part of the trial will determine the role of adjuvant IFN- α 2b in patients with minimal nodal disease. Patients who had a histologically negative SLN then had further molecular analysis of the node by PCR. Patients with a PCR negative node will be observed, but those with a PCR positive node were randomized to observation, CLND, or CLND with IFN- α 2b. This part of the trial will determine the value of molecular staging by PCR, and will determine the optimal treatment for patients upstaged by PCR.


Clinical Trials Involving SLN Mapping for Breast Cancer

Three prospective randomized clinical trials are evaluating SLNB in women with breast cancer. NSABP B-32 opened in 1999 and randomized women with clinically node negative early stage breast cancer to undergo SLNB alone, or SLNB with mandatory ALND. For patients randomized to the SLNB alone arm, if the node was positive then an ALND was offered. The goal of the NSABP B-32 trial is to determine the value of SLNB alone compared to SLNB followed by ALND for patients with a histologically negative SLN.

The American College of Surgeons Oncology Group (ACOSOG) developed the Z0010 trial to assess the value of detecting micrometastatic disease in the SLN as compared to the bone marrow. Women with early stage breast cancer who were candidates for breast-conservation therapy were offered SLNB and bone marrow biopsy. The SLN is analyzed by IHC and the bone marrow is analyzed by immunocytochemistry. The prognostic value of each will be compared as predictors of survival. The ACOSOG Z0011 trial is an extension of the Z0010 trial, although patients can now be enrolled in Z0011 without first being in Z0010. In Z0011, women who undergo breast-conservation therapy and SLNB are randomized only if the SLNB is positive. Randomization is to observation or to ALND. All patients (in both arms) are then offered breast radiation and appropriate adjuvant chemotherapy. The goal of the study is to assess the efficacy of SLNB alone compared to SLNB with ALND for patients with a positive SLN.

Conclusion

Sentinel lymph node mapping and biopsy is a relatively new technique for staging and treating patients with melanoma or breast cancer. With tremendous benefits and minimal risk, SLNB has become so widely adopted that elective lymph node dissections are practically antiquated. Although this procedure has a learning curve, most surgeons who treat breast cancer and melanoma have been

able to incorporate this technique into their practice. Results from the clinical trials presented in this article will answer many questions about SLN mapping and will likely change the management of these diseases significantly over the next few years. A multidisciplinary team approach will certainly help physicians evolve as novel therapies and treatment algorithms are developed. 

Joseph J. Bennett, MD, is with the Department of Surgery, Helen F. Graham Cancer Center, Christiana Care Health System in Newark, Del.

References

- 1Jemal A, Tiwari RC, Murray T, et al. Cancer statistics, 2004. *CA Cancer J Clin.* 2004; 54:8-29.
- 2Balch CM, Buzaid AC, Soong SJ, et al. New TNM melanoma staging system: linking biology and natural history to clinical outcomes. *Semin Surg Oncol.* 2003; 21:43-52.
- 3Lyman GH, Giuliano AE, Somerfield MR, et al. American Society of Clinical Oncology guideline recommendations for sentinel lymph node biopsy in early-stage breast cancer. *J Clin Oncol.* 2005; 23:7703-7720.
- 4Balch CM, Soong S, Ross MI, et al. Long-term results of a multi-institutional randomized trial comparing prognostic factors and surgical results for intermediate thickness melanomas (1.0 to 4.0 mm). Intergroup Melanoma Surgical Trial. *Ann Surg Oncol.* 2000; 7:87-97.
- 5Loudon L, Petrek J. Lymphedema in women treated for breast cancer. *Cancer Pract.* 2000; 8:65-71.
- 6Hughes TM, Thomas JM. Combined inguinal and pelvic lymph node dissection for stage III melanoma. *Br J Surg.* 1999; 86:1493-1498.
- 7Morton DL, Wen DR, Wong JH, et al. Technical details of intraoperative lymphatic mapping for early stage melanoma. *Arch Surg.* 1992; 127:392-399.
- 8Thompson JF, McCarthy WH, Bosch CM, et al. Sentinel lymph node status as an indicator of the presence of metastatic melanoma in regional lymph nodes. *Melanoma Res.* 1995; 5:255-260.
- 9Veronesi U, Paganelli G, Viale G, et al. Sentinel lymph node biopsy and axillary dissection in breast cancer: results in a large series. *J Natl Cancer Inst.* 1999; 91:368-373.
- 10Krag D, Weaver D, Ashikaga T, et al. The sentinel node in breast cancer—a multicenter validation study. *N Engl J Med.* 1998; 339:941-946.
- 11McMasters KM, Tuttle TM, Carlson DJ, et al. Sentinel lymph node biopsy for breast cancer: a suitable alternative to routine axillary dissection in multi-institutional practice when optimal technique is used. *J Clin Oncol.* 2000; 18:2560-2566.
- 12Clary BM, Brady MS, Lewis JJ, et al. Sentinel lymph node biopsy in the management of patients with primary cutaneous melanoma: review of a large single-institutional experience with an emphasis on recurrence. *Ann Surg.* 2001; 233:250-258.
- 13Spanknebel K, Coit DG, Bieligk SC, et al. Characterization of micrometastatic disease in melanoma sentinel lymph nodes by enhanced pathology: recommendations for standardizing pathologic analysis. *Am J Surg Pathol.* 2005; 29:305-317.
- 14Ross GL, Shoaib T, Scott J, et al. The impact of immunohistochemistry on sentinel node biopsy for primary cutaneous malignant melanoma. *Br J Plast Surg.* 2003; 56:153-155.
- 15Wong SL. The role of sentinel lymph node biopsy in the management of thin melanoma. *Am J Surg.* 2005; 190:196-199.
- 16Sondak VK, Taylor JM, Sabel MS, et al. Mitotic rate and younger age are predictors of sentinel lymph node positivity: lessons learned from the generation of a probabilistic model. *Ann Surg Oncol.* 2004; 11:247-258.
- 17Ferrone CR, Panageas KS, Busam K, et al. Multivariate prognostic model for patients with thick cutaneous melanoma: importance of sentinel lymph node status. *Ann Surg Oncol.* 2002; 9:637-645.
- 18Morton D, Thompson J, Cochran A, et al. Interim results of the Multicenter Selective Lymphadenectomy Trial (MSLT-I) in clinical stage I melanoma. American Society of Clinical Oncology Annual Meeting. 2005.