

# CAR-T Navigation

Emily Ebelhar, BSN, RN

Bone Marrow Transplant and Immune Cell Therapy Nurse Coordinator

*IU Health*



# Objectives

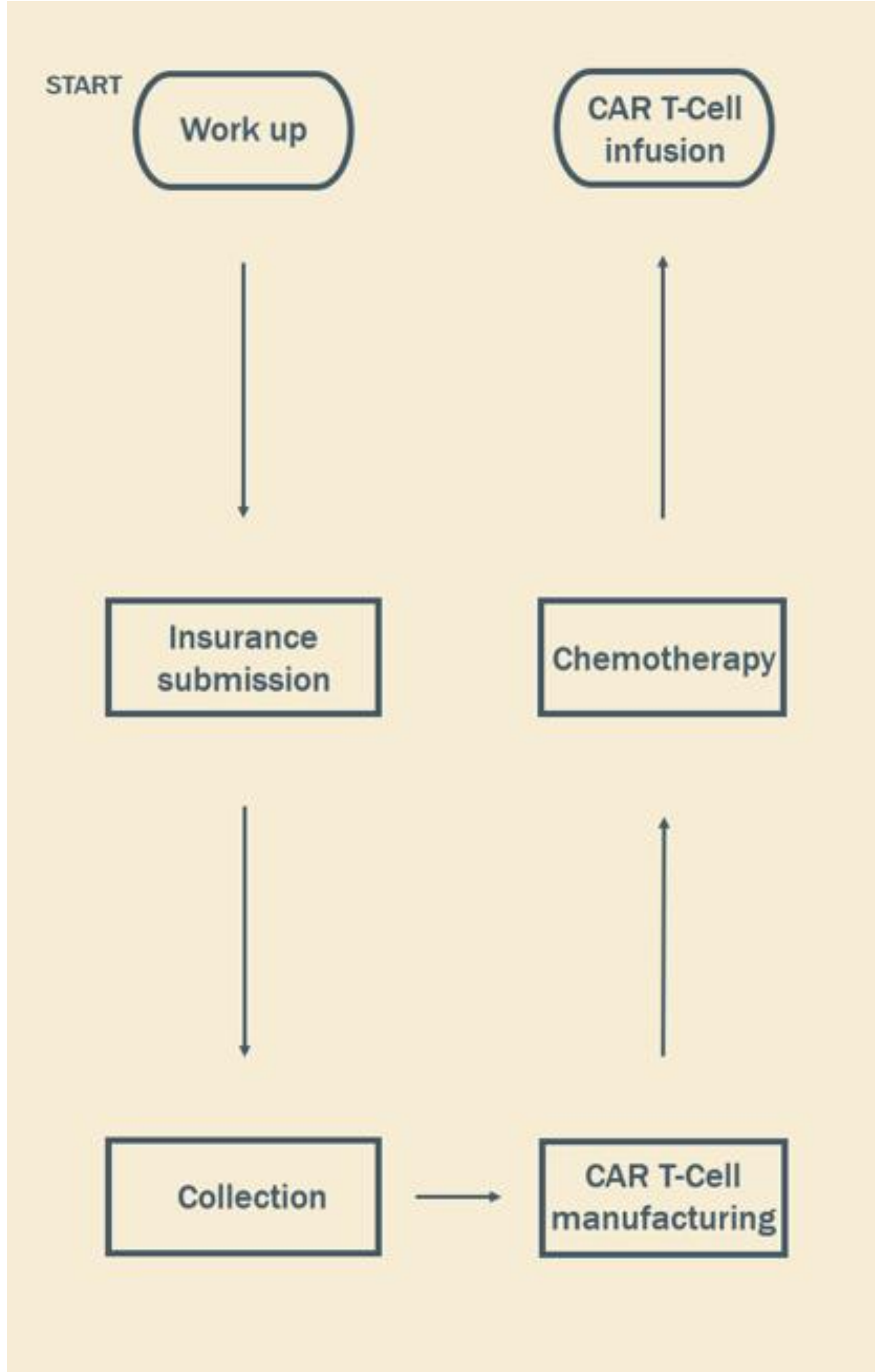
- What is a Navigator?
- Real life patient cases
  - Navigating unique social situations
  - Going beyond the normal standards
- Questions

# What is a Navigator?

# Let's Meet Our First Patient

John Jones

- 77-year-old, Male
- Stage IVB Diffuse Large B-Cell Lymphoma
- Previous treatment included:
  - 6 cycles of Pola-R-CHP completed from June 2023 through September 2023. Post treatment PET showed complete metabolic response.
  - Unfortunately, the patient relapsed in May of 2024, and was treated with R-GemOX. Post treatment PET showed disease progression.



# Let's Meet Our Second Patient

Mary Doe

- 47-year-old, Female
- Diffuse Large B-Cell Lymphoma
- History of: hypertension and end-stage renal disease (requiring hemodialysis)
- Previous treatment included:
  - 6 cycles of R-CHOP, with dose reduction. Post treatment PET showed a mixed response.

# Manufacturing

- Out of Spec product
- Elevated IFN levels, due to end-stage renal disease
- Expanded access protocol (EAP) creation

**Questions?**



**Thank you**