

IMAGING REQUESTS – Chart Navigation


1. Reason for Exam

- a. In the side referral toolbar, providers should document their reasons for the exam, this is a good place to look and get an idea of why and where to find information in the chart
- b. An Oncologist might order an imaging scan for any of the following reasons:
 1. **SUSPECTED CANCER** - imaging is requested prior to tissue confirmation when the clinical picture is typical for a cancer
 2. **INITIAL WORKUP/STAGING** - imaging is requested after tissue confirmation and usually prior to consideration of definitive surgery or other oncologic therapies
 3. **RESTAGING** - imaging is requested to measure the cancer's response to treatment such as chemotherapy
 4. **SURVEILLANCE** - follow-up imaging for individuals assumed to have no known disease, stable or clinically insignificant disease. Active treatment with chemo or radiation has ended
 5. **RECURRENCE** - imaging requested to evaluate the return of the cancer

Order Information ^	
Encounter Summary	
Order Details	
Procedure:	CT CHEST W CONTRAST
Linked chargeables:	CT THORAX W/DYE [71260 (CPT®)] HC CT-CHEST(THORAX) W/CONTRAST [35000015]
Associated diagnosis:	Z85.810 (ICD-10-CM) - History of malignant neoplasm of tongue
Date:	10/9/2019
Provider:	Dennis D. Beckworth, MD
Department:	MMOP CLINICAL ONCOLOGY- MERIDIAN
Reason for exam:	Hx: Base of tongue Ca, new LUL 2mm nodule, eval disease status

2. Pathology Results

- a. **Does the patient have a pathology confirmed cancer diagnosis?**
 - Navigate to patient's chart and look under Pathology tab, find TISSUE EXAM, this is the latest Pathology, near the middle of the Pathology report, you will see the cancer diagnosis ICD-10 code.
 - If patient does NOT have a pathology, review the chart for Progress Notes or Triage telephone encounters for scan mentions to justify why imaging is necessary.
 - This is rare, usually indicates that the patient needs imaging emergently and Bone Marrow Biopsy has not been performed yet or is pending results.

 10/04/2019 9:00 AM TISSUE EXAM

- The Pathology report will tell you type of cancer, in addition to any differentiated characteristics

FINAL DIAGNOSIS

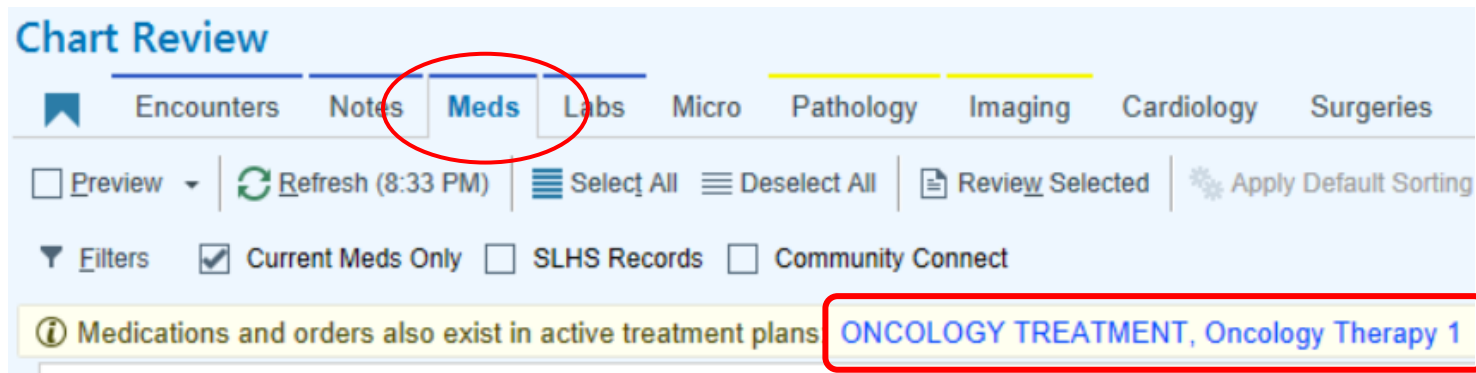
BONE LESION, LEFT ILIAC, BIOPSY:

METASTATIC POORLY DIFFERENTIATED NEUROENDOCRINE CARCINOMA.

3. Treatment Status (Understanding Chemotherapy Regimens)

- o Has the patient completed all planned therapy?

- o If the ordering provider is a Medical Oncologist, the patient's treatment is chemotherapy
- o The quickest way to find out if the patient has an active chemotherapy regimen is to look in the Chart under the Meds tab, you will see a blue hyperlink labeled "Oncology Treatment Plan" or "Oncology Therapy"
 1. Treatment plan - Regimen given to patients to treat the cancer
 2. Therapy plan - Regimen given to patients to treat the effects of cancer treatment.



- o Once you click on the hyperlink, you will see the treatment regimen, this will show you the name of the Oncology Treatment the patient is on, you can then click on the active treatment name, this will take you to the treatment regimen and you will see how far along the patient is in their treatment

Recurring Treatments

Name	Type	Plan dates	Plan Provider
Active			
FOLFOX 6 Oxaliplatin / Leucovorin / Fluorouracil	ONCOLOGY TREATMENT	9/17/2019 - Present	Silvana Z. Bucur, MD
SLHS ONCOLOGY HYDRATIONS	Oncology Therapy 1	10/8/2019 - Present	Silvana Z. Bucur, MD

- o You will be able to see the name of the medication(s) the patient is on and the number of cycles the patients has completed. (example: Treatment Plan Regimen - FOLFOX 6 Oxaliplatin / Leucovorin / Fluorouracil)
 1. If patient is on Cycle 6 of 12, the scan is usually for treatment evaluation, to check patient's response to chemotherapy

- 2. If patient is on Cycle 12 of 12, the scan is for restaging, to measure if the tumor has shrunk or progressed
- You will see what Line of Therapy the patient is on
 1. **Adjuvant** - After surgery (in this case the tumor was usually small enough to be surgically resected, chemo and/or radiation is then given to target the remaining cells to eliminate the risk of the tumor returning)
 2. **Neoadjuvant** - Before surgery (in this case the tumor is too large to be surgically removed, chemo and/or radiation is given first to shrink the tumor and make it small enough to be surgically removed)
- You will also see the Treatment Goal
 1. **Curative** - intent is to cure
 2. **Palliative** - intent is pain management

Treatment Plan Information

FOLFOX 6 Oxaliplatin / Leucovorin / Fluorouracil

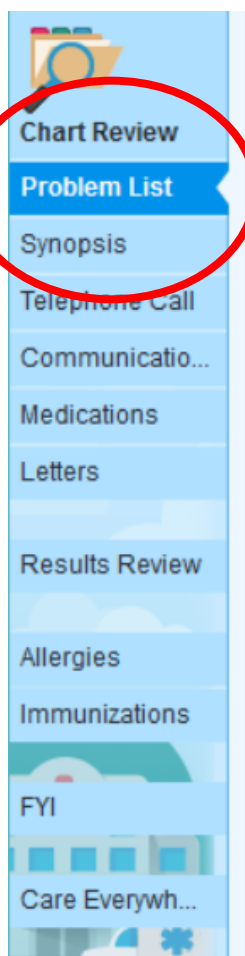
Current Cycle	Treatment Dates	Line of Treatment	Treatment Goal	Treatment Plan Provider	Treatment Department	Status	Auth Status
2 of 12 cycles	9/23/2019 to 3/4/2020	Adjuvant	Curative	Silvana Z. Bucur, MD	St Luke's Chemo Infusion IPI - Meridian	Active	

- Once you scroll down, you will see the cycle intervals and dates the patient had treatment, clicking on each interval opens the cycle and shows you the name of drug and dose.

Day 1, Cycle 3 (14-day cycle)	Planned for 10/28/2019
Day 3, Cycle 3 (14-day cycle)	Planned for 10/30/2019
Day 1, Cycle 4 (14-day cycle)	Planned for 11/11/2019
Day 3, Cycle 4 (14-day cycle)	Planned for 11/13/2019

4. Problem List in Chart

- a. Quickest way to get a fast synopsis of patient's cancer and the treatments the patient has had is under the Problem List in the Chart.
 - o Here you will find clinical information such as staging, ER/PR, HER2 status, molecular mutations, surgical interventions
 1. ER (Estrogen Receptor), PR (Progesterone Receptor)
 2. HER-2 (human epidermal growth factor receptor 2)



Chronic pain (From Hx) ⌵

Metastatic breast cancer (HCC) 📄 📄 [Edit Overview](#) ✎ [Change Dx](#) ✅ [Resolve](#) -3 days [Bucur, Silvana Z., MD](#) ⬆

✎ [Details](#) ℹ [Code: C50.919](#) [Sort Priority: Unprioritized](#) [Noted: 09/07/2017](#)

Cancer Staging

Date	Classification	Stage	Status
9/14/2017	Pathologic	Stage IV (M1)	Signed by Courtney M. Woolston, DNP on 4/4/2019

📄 [Overview](#) Edited: Courtney M. Woolston, DNP 4/3/2019

Diagnosis



















1. 2004 left breast cancer receptor positive. Staging specifics unknown. Obtaining medical records
2. September 2017 metastatic breast cancer **ER 90% PR 80% HER-2 negative**

Treatment

1. Per patient report, left breast cancer diagnosed 2004. Treatment St. Alphonsus Hospital. Left mastectomy, chemotherapy, left chest wall radiation and hormonal blockade truncated due to increased depression
2. September 14, 2017 right iliac crest biopsy metastatic carcinoma of the mammary origin ER 90% PR 80% HER-2 negative
3. Letrozole initiated Dr. Bucur October 5, 2017
4. Palliative radiation therapy sacrum and bilateral hips Dr. Tonya Kuhn October 2017
5. Ibrance initiation Nov 2017.
6. Monthly Zometa, started Jan 26, 2018. Patient last received 3/7/19

5. Labs for Imaging justification

- Each cancer and its respective chemotherapeutic regimen come with specific side effects. For cancer patients on chemotherapy, labs are closely monitored as they can indicate toxicity to chemotherapy. One of the most important labs are the Liver Enzyme tests.
 - i. You might be asked on an auth request if a patient has an elevated ALT/AST, Bilirubin, Alkaline Phosphatase
 1. This is called hepatotoxicity, when a condition or a treatment (such as medications or chemotherapy) has caused damage to the liver.
 2. This is highly dangerous, as it indicates that the patient's liver is having trouble filtering the chemotherapy toxins and chemotherapy might need to be paused or changed, thus medical necessity for a scan is justified.
 3. You will find the results of ALT/AST, ALK PHOS, Bilirubin, BUN, Creatinine under the **COMPREHENSIVE METABOLIC PANEL** under the Lab tab in the patient's chart.

 Comprehensive Metabolic Panel	
Status: Final result	
	Ref Range & Units
 SODIUM	135 - 144 mmol/L
 POTASSIUM	3.5 - 5.5 mmol/L
 CHLORIDE	98 - 107 mmol/L
 TOTAL CO2	22 - 32 mmol/L
 ANION GAP	7 - 15 mmol/L
 GLUCOSE	60 - 100 mg/dL
 CALCIUM	8.4 - 10.6 mg/dL
 BUN	7 - 17 mg/dL
 CREATININE	0.52 - 1.04 mg/dL
 GFR IF AFRICAN AMERICAN	>=60 ml/min/1.73m2
 GFR IF NON AFRICAN AMERICAN	>=60 ml/min/1.73m2
 PROTEIN TOTAL	6.3 - 8.2 g/dL
 ALBUMIN	3.5 - 5.0 g/dL
 TOTAL BILIRUBIN	0.2 - 1.3 mg/dL
 ALK PHOS	38 - 126 U/L
 AST(SGOT)	15 - 46 U/L
 ALT(SGPT)	<35 U/L

6. Tumor Markers

- In cancer patients, labs are monitored very closely. Though there aren't tumor markers for every type of cancer, a tumor marker is a substance that is made by the body because a cancer is present. Or it can be made by the cancer itself. Some of these markers are specific to one cancer. Some are seen in several types of cancer. The markers can be found in the blood, urine or tissues.
- Tumor markers are most often used to track how a patient's cancer responds to treatment. If the level is going down, the treatment is working. If it goes up, the cancer may be growing. An Oncologist might request a scan given a rising tumor marker.

Tumor Marker	Cancers Associated with Elevated Results
CA 15-3 Cancer Antigen 15-3 or Carbohydrate Antigen 15-3	Breast** (often not elevated in early stages of breast cancer), lung, ovarian, endometrial, bladder, gastrointestinal
CA 19-9 Cancer Antigen 19-9 or Carbohydrate Antigen 19-9	Pancreas** and colorectal, liver, stomach and biliary tree cancers
CA 125 Cancer Antigen 125 or Carbohydrate Antigen 125	Ovarian cancer** breast, colorectal, uterine, cervical, pancreas, liver, lung
CA 27.29 Cancer Antigen 27.29 or Carbohydrate Antigen 27.29	Breast** (best used to detect recurrence or metastasis). Colon, gastric, liver, lung, pancreatic, ovarian, prostate cancers
CEA Carcinoembryonic Antigen	Colorectal cancers ** Breast, lung, gastric, pancreatic, bladder, kidney, thyroid, head & neck, cervical, ovarian, liver, lymphoma, melanoma
LDH Lactic Dehydrogenase	Lymphoma, melanoma, acute leukemia, seminoma (germ cell tumors)
PSA Prostate Specific Antigen	Prostate**

7. MRI for Hematology Patients

- Hepatic iron overload is commonly associated with hereditary hemochromatosis, transfusion-related iron overload, and chronic hepatopathies.
 - Hemochromatosis (MRI of the Liver): MRI is the most sensitive imaging modality for the diagnosis of hemochromatosis and can estimate iron concentration within the liver, thus forestalling the need for repeated liver biopsies. ****You will be asked if patient is a candidate for Therapeutic Phlebotomy and/or Chelation Therapy, patients are candidates for both, though MSTI does NOT do Chelation Therapy.**

8. Nuclear Bone scan: A type of x-ray called a bone scan may be performed to diagnose cancer in the bones or bone metastases. In this test, low level radioactive particles are injected into a vein. They circulate through the body and are selectively picked up by the bones. A high concentration of these radioactive particles indicates the presence of rapidly growing cancer cells in the bones.

9. Skeletal survey: A skeletal survey may be performed to diagnose cancer in the bones that causes extra build-up of bone, called blastic lesions. A skeletal survey is a type of X-ray. Conventional X-rays are used to image small sections of the body that may be of concern, such as the spine; whereas skeletal surveys image all areas of the body.

10. Adult Transthoracic Echocardiogram: Used as part of pretesting to assess ejection fraction prior to potentially cardiotoxic chemotherapy/biotherapy. Particularly for Breast Cancer.

- In this case, choose “LV dysfunction” then “Treatment w/Cardiotoxic medication” options

DIAGNOSTIC CODE:

- ⊖ C50.812 Malignant neoplasm of overlapping sites of left female breast

CLINICAL SCENARIO:

Select the main reason from the list below for the order request.

- + CAD (Coronary artery disease)
- + Congenital heart disease
- + Disease of any heart valve (Valvular disease)
- 1. + LV dysfunction/CHF/Cardiomyopathy (Cardiotoxic, chemo, heart transplant)**
- + Signs, symptoms, or abnormal tests (eg, shortness of breath or chest pain)
- + Other diagnosis or reasons for imaging (click for more options)

CLINICAL SCENARIO

LV dysfunction/CHF/Cardiomyopathy (Cardiotoxic, chemo, heart transplant)

CLINICAL DETAILS

* Select the reason for ordering this exam.

- 2. Treatment with a cardiotoxic medication (for example, chemotherapy) ⓘ**
- History of heart transplant
- Undergoing evaluation for heart transplant
- Suspected or known myocarditis
- Known or suspected ventricular dysfunction, heart failure, or cardiomyopathy
- None of these apply

11. AIM Phases of the care continuum are defined as follows:

- **Screening** – testing in the absence of signs or symptoms of disease
- **Diagnostic Workup** – testing based on a reasonable suspicion of a condition or disorder, usually due to the presence of signs or symptoms
- **Management** – testing to direct therapy of an established condition, which may include preoperative or postoperative imaging, or imaging performed to evaluate the response to nonsurgical intervention
 - For patients with residual disease after completion of treatment, the criteria for “Management” apply
- **Surveillance** – periodic assessment following completion of therapy in the absence of measurable disease
 - “Surveillance” specifically refers only to patients with no measurable disease.

12. Cancer Staging:

Most common is a 0-5 scaling system:

- **Stage 0:** Abnormal cells are present, but have not spread to nearby cells, also called carcinoma in situ, or CIS.
 - *CIS is not cancer, but it may become cancer.
- **Stages 1, 2, 3:** Cancer is present. Higher stages indicate larger tumors and a more extensive spread into nearby tissues
- **Stage 4:** The cancer has spread to other areas of the body, referred to as metastatic

Further, the following terms are used to describe the various cancer stages:

- **In Situ:** Abnormal cells are present, but have not spread to nearby tissues
- **Localized:** Cancer has not spread beyond the place where it first developed
- **Regional:** Cancer has spread to nearby lymph nodes, tissues, or organs
- **Distant:** Cancer has spread to distant parts of the body
- **Unknown:** There is not enough information to determine a stage

13. Lung Cancer

- **Non-Small Cell Lung Cancer** accounts for about 85 percent of lung cancers and includes:
 - **Adenocarcinoma**, the most common form of lung cancer in the United States among both men and women
 - **Squamous cell carcinoma**, which accounts for 25 percent of all lung cancers;

- Large cell carcinoma, which accounts for about 10 percent of NSCLC tumors.
- Small Cell Lung Cancer accounts for the remaining 15 percent of lung cancers in the United States. They tend to grow more quickly than NSCLC tumors

14. PET Scan FYIs:

- The "limited area" PET is used when only a single body area is studied or when the scan does not extend from skull base to mid-thigh. For example, the "limited area" should be used for a scan that extends from the skull to the groin.
- The "whole body" PET is used for scans that extend from the top of the head, also known as the vertex, down to the feet or lower leg. This type of scan is most commonly performed for melanoma.
- If the scan does not include all the required area, it should be reported as a "skull base to mid-thigh" PET.

15. NCCN (National Comprehensive Cancer Network) guidelines for Imaging:

- <https://www.nccn.org/professionals/imaging/default.aspx>
- Can link account through United Healthcare (Optum ID)
- All indications listed on NCCN; can search by disease, modality and/or diagnosis. Use Clinical Setting and choose disease type.

NCCN Guideline: -- Select a NCCN Guideline --

Clinical Setting: -- Select a Clinical Setting --

Purpose: -- Select a Purpose --

Modality: -- Select a Modality --

ICD-10: -- Select an ICD-10 Code --

Clinical Setting	Guideline Page	Category of Evidence	Stage	Indication	Imaging Recommendation	Purpose	Imaging Notes
Active (symptomatic) Myeloma	MYEL-1	2A		Initial workup	<ul style="list-style-type: none"> Skeletal survey or whole body low-dose CT Useful under some circumstances: <ul style="list-style-type: none"> Whole body or skeletal MRI with contrast or whole body FDG PET/CT Echocardiogram 	Diagnostic	Additional testing (whole body or skeletal MRI or whole body PET/CT) recommended to discern active from smoldering myeloma, if skeletal survey is negative. If FDG PET/CT has been done, then skeletal survey is not needed.
Active (symptomatic) Myeloma	MYEL-4	2A		Post primary treatment	As clinically indicated: <ul style="list-style-type: none"> Skeletal survey or whole body low-dose CT Whole body or skeletal MRI with contrast or <ul style="list-style-type: none"> Whole body FDG PET/CT 	Follow-up/Surveillance	Consider using the same imaging modality used during the initial workup for follow-up assessments.
Active (symptomatic) Myeloma	MYEL-5	2A		Response after primary therapy; Post stem cell transplant or continuous myeloma therapy or maintenance therapy	As clinically indicated: <ul style="list-style-type: none"> Skeletal survey or whole body low-dose CT Whole body or skeletal MRI with contrast or <ul style="list-style-type: none"> Whole body FDG PET/CT 	Follow-up/Surveillance	Consider using the same imaging modality used during the initial workup for follow-up assessments.
Active (symptomatic) Myeloma	MYEL-6 MYEL-D (1 of 3) MYEL-D (3 of 3)	2A		Post allogeneic or autologous stem cell transplant; Response or stable disease; Post maintenance therapy or observation	As clinically indicated: <ul style="list-style-type: none"> Whole body or skeletal MRI with contrast Whole body low-dose CT Whole body FDG PET/CT 	Treatment Response Assessment	All response categories require two consecutive assessments made any time before starting any new therapy, however, radiographic studies are not required to satisfy these response requirements except for the use of FDG PET/CT if imaging MRD-negative status is reported. Plasmacytoma measurements should be taken from the CT portion of the PET/CT, or the MRI or dedicated CT scans, where applicable.